

# MODULE 7: PEDIATRIC URINARY TRACT INFECTIONS

**KEY WORDS:** Cystitis, vesicoureteral reflux (VUR), dysuria, hematuria, pyelonephritis, hydronephrosis, UTI

## LEARNING OBJECTIVES

At the end of this clerkship, the medical student will be able to:

1. Outline the socioeconomic impact and epidemiologic characteristics of pediatric UTIs
2. Describe the differences in clinical presentation between lower and upper UTIs
3. Outline the risk factors associated with viral and fungal pediatric UTIs
4. Describe the anatomic and functional sequelae of untreated pediatric UTIs
5. List 3 possible causative organisms in non-bacterial, pediatric UTIs
6. Summarize the diagnostic evaluation of pediatric UTIs
7. Outline the treatment goals and complications associated with antibiotic prophylaxis for pediatric UTIs
8. Delineate 5 congenital/anatomical causes and 3 acquired causes of pediatric UTIs
9. Summarize the management approaches for congenital/anatomic and acquired causes of pediatric UTIs

## EPIDEMIOLOGY

Pediatric UTI's are a major health care problem. Urinary tract infections (UTIs) affect 3% of children every year. Annually, pediatric UTI's account for over 1 million office visits in the U.S. (0.7% of all physician visits by children). Furthermore, each year there are approximately 13,000 pediatric admissions for pyelonephritis, with inpatient costs exceeding \$180 million. Throughout childhood, the risk of UTI is 8% for girls and 2% for boys. Sexually active girls experience more UTIs than sexually inactive girls. However, during the first year of life, more boys than girls get UTI's, with a tenfold increased risk for uncircumcised compared to circumcised boys.

## CLINICAL PRESENTATION

The anatomic location of the UTI is germane to etiology and clinical presentation. Regardless of UTI location, infants and many young children cannot describe their symptoms; hence it is critical to understand the observable signs and symptoms of infection to make the diagnosis. Lower UTI's include bladder infections (cystitis),

whereas upper UTI's include pyelonephritis and perinephric and renal abscess. Cystitis is second in frequency only to respiratory infection as a reason for pediatric medical visits. Classic symptoms of cystitis include urinary frequency, urgency, dysuria, hematuria, suprapubic pain, sensation of incomplete emptying, and often, incontinence. Non-specific symptoms can include poor feeding, irritability, lethargy, vomiting, diarrhea, ill appearance, and abdominal distension (Table 1). Fever and flank pain are unusual symptoms for lower UTI, but fever can more often be a sign of lower UTI in children as compared to adults.

**TABLE 1. SYMPTOMS OF A PEDIATRIC UTI**

*Lower Urinary Tract*

Classic Non-specific

Frequency	Hematuria
Poor appetite	Vomiting
Urgency	Diarrhea
Irritability	Abdominal distension
Dysuria	*Incontinence
Lethargy	*Incomplete emptying

*Upper Urinary Tract*

Classic Non-specific

Frequency	Hematuria
Poor appetite	Vomiting
Urgency	Diarrhea
Irritability	Abdominal distension
Dysuria	*Fever
Lethargy	*Flank pain

(\*) Denotes differences in Upper and Lower Urinary Tract

Pyelonephritis, and to a lesser degree renal abscesses, typically begin as a lower UTI that proceeds to an upper UTI as the infections ascends. However, pyelonephritis and renal abscesses can also result from hematogenous spread of infection (e.g., bacteremia). Symptoms that occur with upper UTI's overlap those for cystitis, in part because cystitis is common in both. In upper UTI's, flank pain and fevers (typically intermittent pain and >39°C) are more pronounced and important (Table 1).

## FUNGAL AND VIRAL UTI

Fungi and viruses can also cause cystitis in certain settings and with associated risk factors. Fungi are the second most common cause of nosocomial UTI in children, and can spread systemically and can be life-threatening. Risk factors for fungal UTI's include the use of invasive devices (peripheral and central vascular access lines, drains, and catheters), previous broad-spectrum antibiotic exposure, and systemic immunosuppression. A true candiduria infection can be difficult to diagnose, since it can represent colonization, contamination, or infection, and may or may not have associated symptoms. Suggestive diagnostic criteria include: Lack of pyuria and  $4 > 10$  colony forming units/mL (in neonates) from a urine culture obtained by urethral catheterization. The potential for candiduria to develop into invasive candidiasis in the neonatal intensive care unit (NICU) is significant. Risk factors for this progression include prematurity, congenital urinary tract abnormalities, parenteral nutrition, respiratory intubation, and umbilical artery or intravenous catheterization. Furthermore, the kidney is the most commonly affected organ in candidiasis, with "fungus balls" in the renal pelvis/calices, representing a life threatening infection. As such, renal and bladder sonography is important in the evaluation of neonates with candiduria.

There is no consensus regarding the treatment of pediatric candiduria. Measures include stopping antibiotics if possible, removing or changing indwelling catheters, and antifungal therapy. Commonly used antifungal agents include oral fluconazole and parenteral, intrarenal, or intravesical amphotericin B. In patients with obstruction or failure to improve with medical management, urgent percutaneous nephrostomy tube placement to drain the kidney may be needed. Additional measures include amphotericin B irrigation of the nephrostomy tube, or even nephrectomy in severe cases.

Viral cystitis represents another form of non-bacterial UTI affecting children. Adenovirus types 11 and 21, influenza A, polyomavirus BK, and herpes simplex viruses can cause irritative voiding symptoms, hemorrhagic cystitis and even vesicoureteral reflux or urinary retention. In non-immunized or immunosuppressed children, herpes zoster cystitis presents similarly. Fortunately, these forms of cystitis are self-limited. Immunosuppressed children undergoing kidney or bone marrow transplantation, or those receiving chemotherapy are especially susceptible to viral cystitis, including those caused by cytomegalovirus and adenoviruses 7, 21, and 35. Antivirals such as ribavirin and vidarabine may be helpful when viral cystitis is diagnosed.

## SEQUELAE

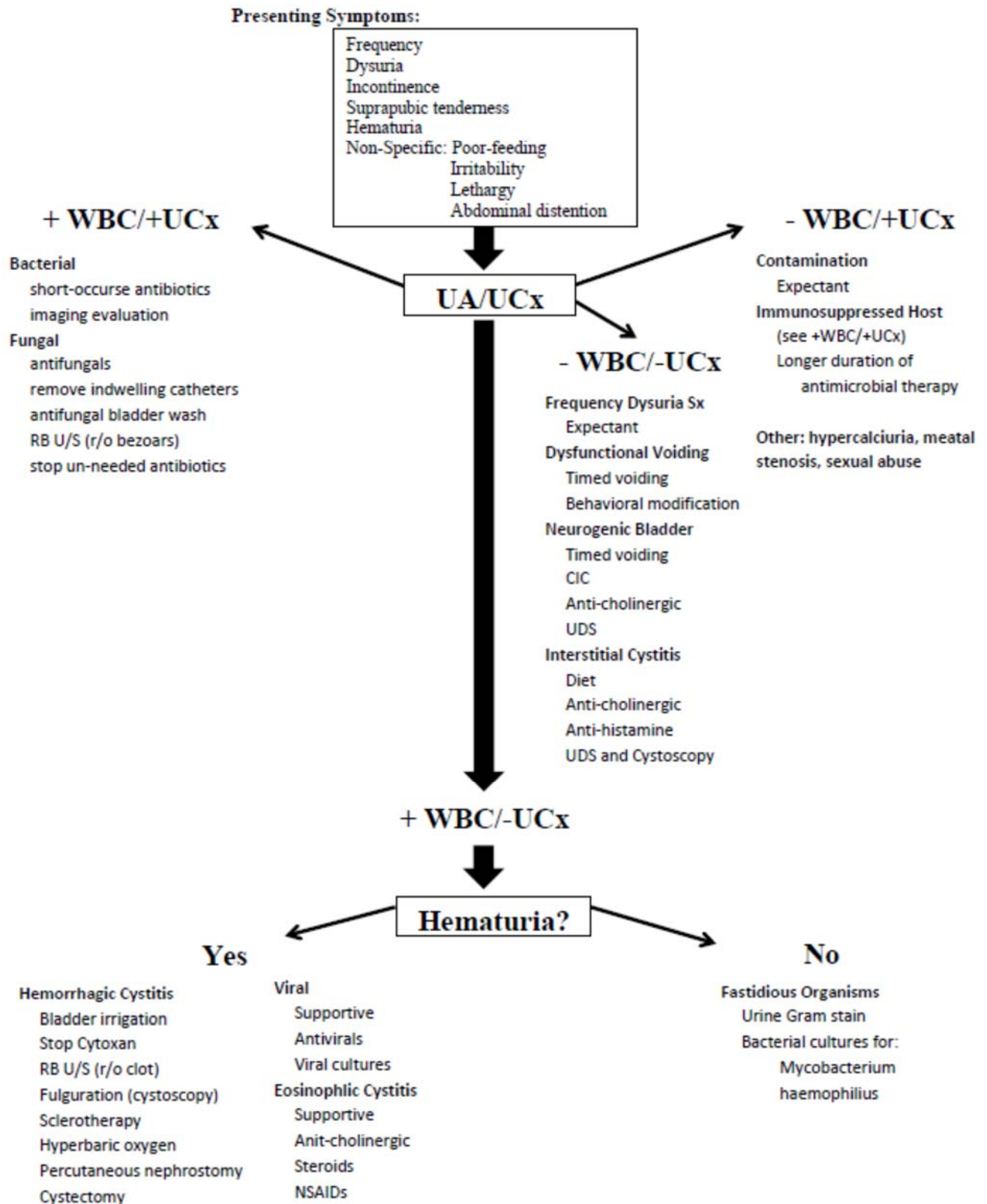
Acute sequelae of pediatric bacterial UTI include the spread of infection outside the urinary tract, resulting in epididymitis or orchitis in boys, and sepsis. The most common serious sequelae of pediatric UTI is that due to pyelonephritis. Chronic pyelonephritis results from persistent infection after acute pyelonephritis and can

result in pyonephrosis, xanthogranulomatous pyelonephritis (XGP), and renal parenchymal scarring with hypertension and renal insufficiency. The accumulation of purulent debris in the renal pelvis and urinary collecting system, known as pyonephrosis, occurs when pyelonephritis is accompanied by urinary tract obstruction. Pyonephrosis requires appropriate antimicrobial therapy and prompt drainage of the urinary tract with percutaneous nephrostomy tube placement or retrograde catheterization.

XGP is a rare clinical entity in children affecting < 1% of cases with renal inflammation. Like pyonephrosis, it develops in the setting of chronic obstruction and infection. The most common pathogens causing XGP are *Proteus* and *E. coli*. XGP is usually unilateral and may extend diffusely throughout the affected kidney and even into the retroperitoneum and cause fibrosis of the great vessels. Radiographically, it can be mistaken for childhood renal tumors. Histologically, the XGP kidney shows evidence of pyonephrosis and xanthoma cells, which are foamy, lipid-laden macrophages. Treatment often involves nephrectomy.

Pyelonephritogenic scarring with renal parenchymal damage occurs more commonly in children than adults for unclear reasons. Renal scarring from pyelonephritis appears to be influenced by at least 5 factors: age, treatment, host immunity, intrarenal reflux, and urinary tract pressures. Future hypertension occurs in at least 10-20% of children with pyelonephritogenic scarring. Hypertension in this setting occurs independent of the degree of renal scarring.

Figure 1. Evaluation and Management for Pediatric Cystitis



Children with recurrent pyelonephritis may also develop progressive renal insufficiency without UTI symptoms. End-stage renal disease from reflux nephropathy (pyelonephritogenic scarring in the setting of vesicoureteral reflux, discussed below) accounts for 7-17% of end-stage renal disease worldwide, and 2% of cases in the U.S.

A thorough history from parents, and the child if possible, and a physical examination are essential in the evaluation of pediatric UTI. Dipstick urinalysis is the most common initial laboratory testing, and may be the most cost-effective screen for infant UTI. Urine cultures and blood cultures (if sepsis is suspected) are the mainstays of diagnosis. Urine from bagged and voided specimens are easier for the child, but have significant false positive rates because of contamination with skin flora (up to 63% for the bag method).

Urethral catheterization and suprapubic aspiration provide the best urine specimens for the diagnosis. The standard definition for bacterial UTI from a voided urine culture is  $10^5$  colony forming units/mL;  $10^3$  to the  $3^{\text{rd}}$  colony forming units/mL for a catheterized specimen (single organism).

The likelihood of UTI can also be estimated based on urine bacterial counts and collection method. The presence or absence of pyuria on urinalysis, along with a urine culture, help make the diagnosis of pediatric UTI (Figure 1). Pyuria with a negative urine culture suggests viral infection, infection with fastidious organisms such as mycobacterium or haemophilus, or noninfectious cystitis. The lack of pyuria and a negative urine culture suggests a non-infectious etiology for cystitis. A positive urine culture along with pyuria likely represents bacterial or fungal infection. A positive urine culture without pyuria may indicate contamination (therefore not a true infection) or an immunosuppressed host.

After establishing the diagnosis of UTI, certain children require additional testing to determine possible causes for their infection. This is important as eradication of UTI with antibiotics may not be possible without correction of underlying structural abnormalities. In addition, the early diagnosis of anatomically based UTIs can prevent or ameliorate long-term sequelae of persistent or recurrent infections. The American Academy Association of Pediatrics has suggested guidelines for radiologic imaging of children with UTIs. Urinary tract imaging is recommended in a febrile infant or young child between the ages of 2 months and 2 years with a first documented UTI. Typically this involves a renal and bladder ultrasound, followed by a voiding cystourethrogram (VCUG) if the ultrasound is abnormal (Figure 2).

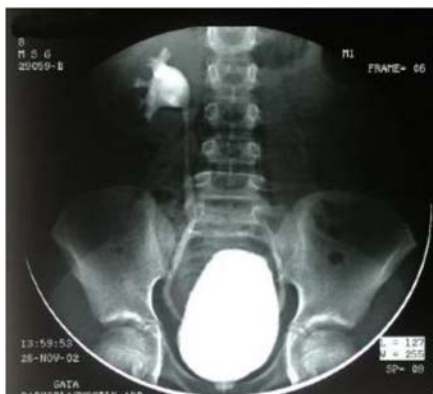

Figure 2. VCUG in a 3 month-old showing R>L vesicoureteral reflux of contrast into the upper urinary tract (ureter and renal pelvis).

The evidence supporting the use of VCUG for older children is less compelling. Imaging is indicated if patients have known anatomic structural abnormalities, unusual uropathogens such as *Proteus* or tuberculosis, fail to improve with appropriate antimicrobial therapy, or have an unclear source of infection. VCUG should be performed as soon as a child is infection-free and bladder irritability has passed, since delaying the VCUG is associated with losing patients to follow-up. Other radiologic studies, including computerized tomography (CT), magnetic resonance imaging (MRI), intravenous urography (IVU), and dimercapto-succinic acid (DMSA) and Technetium (Tc)- 99 m mercaptoacetyl triglyceride (MAG-3) scans have specific indications that will be discussed further.

## **ANTIBIOTIC TREATMENT AND PROPHYLAXIS**

Antibiotic regimens for children with UTI consist of short treatment courses for acute infections and prophylaxis for chronic conditions. The most common class of pathogens isolated in children with uncomplicated cystitis is Enterobacteriaceae. Accordingly, frequently used antibiotics for prophylaxis and treatment include trimethoprim (with or without sulfonamide) and nitrofurantoin, which are effective in 96% of children. Prolonged antibiotic use can alter gut and periurethral flora, leading to bacterial resistance. As an example, children on antibiotic prophylaxis who develop a UTI have a higher incidence of organisms such as *Enterobacter*, *Klebsiella*, and *Proteus*. In addition, widespread use of antibiotics in certain communities has led to increased bacterial resistance to trimethoprim, cephalothin, cephalexin, ampicillin, and amoxicillin. Clearly, antibiotics should be used judiciously to curb increasing bacterial resistance (Table 2).

Table 2: Commonly used oral antibiotics for treating pediatric urinary tract infections

Drug	Dose (mg/kg/day)	Frequency (q hrs)
Penicillins:		
Ampicillin	50-100	6
Amoxicillin	20-40	8
Augmentin	20-40	8
Sulfonamides: trimethoprim- sulfamethoxazole	8	12
Cephalosporins:		
Cephalexin	25-50	6
Cefaclor	20	8
Cefixime	8	12-24
Cefadroxil	30	12-24
Other: nitrofurantoin	5-7	6

(From: Marotte, Lee, Shortliffe, AUA Update Series vol 24; Lesson 19, 2005).

Except for children with vesicoureteral reflux or other structural abnormalities of the urinary tract, the use of antibiotic prophylaxis is controversial. Adolescent girls who are sexually active and susceptible to post-coital cystitis are likely better served by taking short courses of antibiotic treatment when symptoms occur and taking brief, post-intercourse prophylaxis rather than using long-term, prophylactic antibiotic therapy.

## CONGENITAL CAUSES OF UTI

### *Vesicoureteral Reflux*

Vesicoureteral reflux (VUR) is the retrograde flow of urine from the bladder into the ureter and, often, into the renal collecting system. Approximately 40% of children with UTI are subsequently diagnosed with VUR. Primary VUR results from a congenital abnormality of the ureterovesical junction, whereas secondary VUR is caused by high pressure voiding due to neuropathic bladder, bladder outlet obstruction or dysfunctional elimination syndrome. VUR is also a risk factor for pyelonephritis, with potential for renal injury.

The radiographic diagnosis of VUR is primarily made based on upper tract urinary reflux observed on VCUG (Figure 2). Finding hydronephrosis on renal sonography can be variable and not diagnostic of the presence or absence of VUR. DMSA scans are used to assess renal cortical function and monitor for renal scarring. Children with VUR may be managed either medically or surgically, and controversy exists regarding the optimal treatment. Medical management encompasses daily antibiotic prophylaxis



and periodic radiologic reassessment of the urinary tract, since many children spontaneously resolve VUR. Surgical treatment of primary VUR includes open or laparoscopic ureteral reimplantation and subureteric endoscopic injection of various substances, including dextranomer-hyaluronic acid copolymer. Because secondary VUR has other causes than simple anatomical ones, it is imperative that these causes are ruled out in order to allow effective treatment.

### *Ureteropelvic Junction Obstruction*

Ureteropelvic junction (UPJ) obstruction is present in a minority of children born with hydronephrosis, but is the most common surgically correctible reason. This condition results from poor peristalsis of the UPJ or an anatomic abnormality consisting of either an “intrinsic,” narrow segment with muscular discontinuity, or an “extrinsic” anatomic cause from aberrant vessels or a high insertion of the ureter into the renal pelvis (Figure 3). Presenting symptoms include hematuria, UTI, abdominal mass or pain, nausea, or flank pain which worsens with diuresis because of urine production that overwhelms the ability of the UPJ to accommodate an equal volume of drainage and therefore leads to distension of the renal collecting system and ultimately the relatively unyielding renal capsule. Evaluation of UPJ obstruction includes renal ultrasonography, a VCUG to rule out CUR (33% of cases), and a MAG-3 diuretic renogram to look for delayed drainage on the affected side.

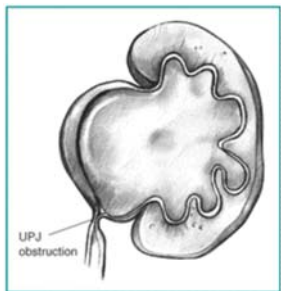


Figure 3. Example of ureteropelvic junction obstruction. (From: kidney.niddk.nih.gov)

Management of UPJ obstruction is dictated by age at diagnosis, symmetry of renal function, severity and stability of hydronephrosis, severity of delayed drainage, and degree of associated symptoms. In some asymptomatic children, UPJ obstruction will resolve spontaneously with expectant management. For many children, however, surgical repair is needed through either open surgical pyeloplasty, the traditional approach, or newer techniques such as laparoscopic pyeloplasty, robot-assisted laparoscopic pyeloplasty, and percutaneous and retrograde endopyelotomy.

### *Ureterocele*

A ureterocele is a cystic dilatation of the terminal, intravesical portion of the ureter (Figure 4). Eighty percent of ureterocele drain the upper pole of a duplex kidney (two collecting systems). Sixty percent of ureterocele have an ectopic orifice in the urethra. A UTI in the first few months of life is a common presentation for a child

with a ureterocele. Sometimes the obstructed upper pole drained by a ureterocele is so hydronephrotic that it is palpable as an abdominal mass.

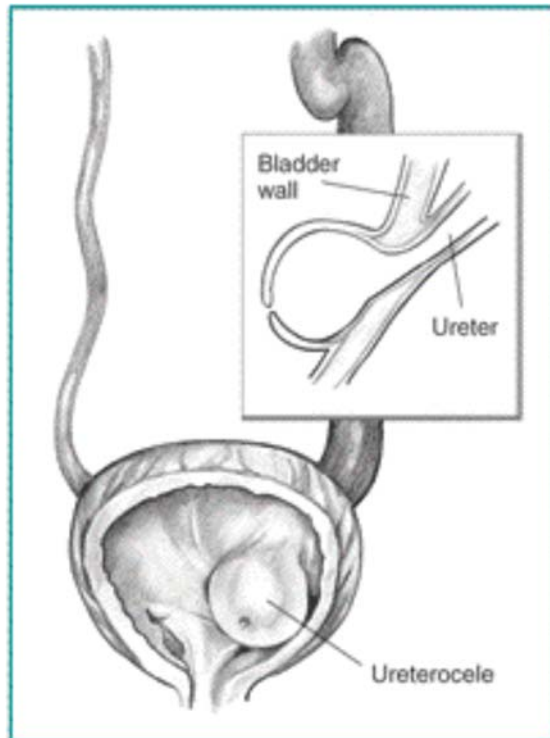


Figure 4. Example of a left sided ureterocele.

(From: kidney.niddk.nih.gov)

Ureteroceles are diagnosed by ultrasonography, which typically shows a cystic intravesical mass in the posterior bladder, a dilated proximal ureter, and a hydronephrotic or dysplastic upper pole of a duplex kidney. Other imaging may demonstrate the “drooping lily” sign, which is a lower pole collecting system displaced downward by a dilated upper pole. This sign can be observed on VCUG, since up to 50% of ipsilateral lower pole moieties will reflux because of local distortion of the lower pole ureteral tunnel/passive flap mechanism. Treatment of ureteroceles is guided by clinical presentation and kidney function. Infants and children presenting with urosepsis are initially treated with endoscopic incision of the ureterocele to drain it and relieve obstruction. Ureteroceles draining nonfunctioning upper pole moieties can be treated by removal (heminephrectomy and ureterectomy) and the ureterocele itself can be removed through open reconstruction. Functioning units can have their drainage systems reconstructed to promote good drainage as needed.

### *Ectopic Ureters*

A ureteral orifice is classified as ectopic when it lies caudal to the normal insertion of the ureter on the trigone of the bladder. Most (70%) of ectopic ureters are associated with complete ureteral duplication. In addition, contralateral duplication occurs in 80% of cases. The ureter branches from the developing mesonephric (Wolffian) duct system and normally reaches its position in the bladder. Ectopic ureters, in boys, can

lie in the bladder neck, prostate, or epididymis. In girls, the orifice usually inserts in the bladder neck, urethra, vagina, cervix, or uterus. Boys with ectopic ureters typically present with UTI or epididymo-orchitis, depending on whether the ectopic orifice is located in the genital ducts. Infant girls often present with UTI, whereas older girls present with continuous incontinence because the ureteral orifice is distal to the bladder neck. Abdominal ultrasonography often shows a dilated ureter draining the upper pole kidney of a duplex system. If the ectopic ureter drains a single system, the kidney may be dysplastic. VCUG often demonstrates reflux in the ectopic system, and may reveal the "drooping lily" sign. In girls, ectopic ureters can be diagnosed by placing a cotton ball in the vagina, filling the bladder with dye, and examining the ball for wetness, but absence of dye. Finally, a MAG-3 study can estimate upper pole function before embarking on surgery.

Surgical management of ectopic ureters is determined by the presence or absence of ureteral duplication, as well as by the function of the subtended kidney. Many upper pole ectopic segments are nonfunctional and can be treated by removal or redirection of the ectopic ureter into the urinary drainage system. Ectopic ureters draining single systems can be reimplanted in the bladder if they drain functional kidneys. Otherwise, nephroureterectomy may be the procedure of choice.

### *Neuropathic Bladder*

Neuropathic bladder can be caused by spinal cord-based disorders such as myelomeningocele and traumatic spinal cord injury. Secondary reflux and incomplete bladder emptying from poor bladder function increases the risk of pyelonephritis. In spina bifida cases with neuropathic bladder, there may be sacral bony defects or simply pigmentation, dimples, lipomas, or tufts of hair. Often, neuropathic bladder due to spinal cord injury or occult spinal dysraphisms is discovered after evaluation of orthopedic problems, difficulty walking, or urinary retention, incontinence or UTI. Management of neuropathic bladder includes neurosurgical intervention, quieting of overactive/high pressure storage with anticholinergic medication, and intermittent catheterization for complete bladder emptying on a regular basis. These patients require particularly careful long-term follow-up of urinary tract function to prevent renal failure from the effects of the abnormally-functioning bladder.

### *Posterior Urethral Valves*

Posterior urethral valves (PUV) are the most frequent cause of congenital bladder outlet obstruction. PUV are obstructing, membranous folds within the lumen of the prostatic urethra, and only occur in boys (Figure 5). Antenatal ultrasound showing a distended, thick-walled fetal bladder and bilateral hydronephrosis is suggestive of PUV. Since 2/3 of amniotic fluid in late gestation is comprised of fetal urine, amniotic fluid production can also be diagnostic factors.

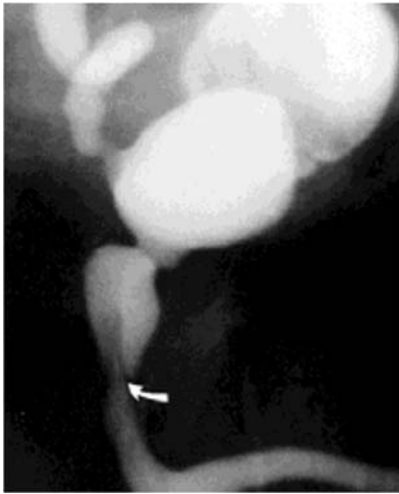


Figure 5: VCUG showing posterior urethral valves (arrow) in a boy.

Oligohydramnios often indicates poor fetal renal function and can lead to pulmonary hypoplasia and postnatal respiratory distress. Clinical presentation after birth includes respiratory difficulty, sepsis, renal failure, and a distended bladder. Less affected boys can present with recurrent UTI or urinary incontinence. One half to one-third of boys with PUV also has VUR and/or renal dysplasia. Acutely ill neonates with PUV are treated by placing a small catheter/feeding tube into the bladder. Definitive early treatment consists of primary endoscopic valve ablation. Other options include cutaneous vesicostomy or bilateral ureterostomies followed by later endoscopic valve ablation. Persistent bladder dysfunction after valve ablation (“valve bladder syndrome”), is an irreversible detrusor alteration from fetal bladder outlet obstruction. The potential for valve bladder syndrome and renal dysplasia leading to renal failure in boys with PUV mandates careful lifelong follow-up. Renal damage incurred up to the point of obstruction relief often dictates ultimate renal function outcome, and is most often not reversible; however, if well-managed, chronic kidney injury can be delayed to some degree.

### *Eagle-Barrett Syndrome*

Also known as Prune Belly or Triad syndrome, this disorder features a deficiency or absence of abdominal wall musculature; dilation of the ureters, bladder, and urethra; and bilateral undescended testes. Renal dysplasia, pulmonary hypoplasia, poor bladder function, and susceptibility to UTI and respiratory tract infections are common. Patients are diagnosed in utero with urinary tract dilation on ultrasound, or noted at birth to have wrinkled, prune-like abdominal wall skin from lack of abdominal wall musculature (Figure 6).

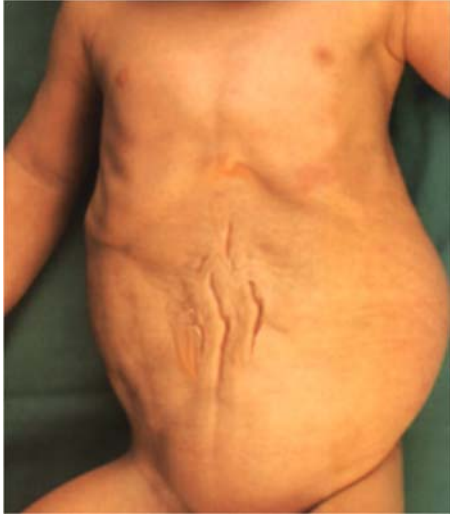

Figure 6. Example of infant with prune belly syndrome 13

Evaluation with VCUG to check for VUR should be considered, but catheterization may result in introduction of bacteria into a stagnant urinary tract. DMSA scans are less invasive and can evaluate renal scarring. In mildly affected patients, lifelong antibiotic prophylaxis may be necessary. More severely affected patients who survive beyond the neonatal period often also require abdominal wall and urinary tract reconstruction along with orchidopexy. In select patients, clean intermittent catheterization may be helpful.

### *Urachal Remnants*

The urachus is the remnant of the allantoic duct, which extends from the anterior bladder wall to the umbilicus. Typically, the urachus obliterates into a fibrous band, but on occasion some or all of this structure persists. A patent urachus may result from bladder outlet obstruction, but more commonly is not associated with other anomalies. The classic presentation is a neonate with a constantly wet umbilicus that leaks during crying or straining. Partially involuted urachal remnants can present later in childhood with infection or growth from accumulation of desquamated tissue. Symptoms include pain, fever, umbilical drainage, periumbilical mass, and UTI. Abdominal ultrasound and VCUG typically reveal urachal remnants, and contrast fistulography may also delineate these structures. Surgical resection is the treatment of choice.

## **ACQUIRED CAUSES OF UTI**

### *Urinary Stones*

In the U.S., urinary calculi occur more often in children from metabolic disorders, whereas in developing regions, they tend to occur more frequently in children with UTI. Known metabolic abnormalities that predispose to stone formation include hypercalciuria, hyperoxaluria, hypocitraturia, hyperuricosuria, cystinuria, and low

urine volume. Symptoms can include fever, dysuria, frequency, urgency, flank pain, hematuria, and UTI, although flank pain often is not seen in children under the age of 5. Approximately 78% of pediatric stones are located in the kidney. The most common stone types, in order of frequency, are calcium oxalate, calcium phosphate, and struvite (infection stones). Renal and bladder ultrasound can identify stones, although in children with a greater skin surface-to-ureter distance, distal ureteral stones may be difficult to see. A KUB can reveal most stones, although pure uric acid stones are radiolucent. CT scans show nearly all stones and also provide anatomic detail that may be useful for operative planning. Spontaneous passage of stones occurs in up to half of children within 2 weeks of diagnosis, and is related to stone size. Otherwise, removal or breakup of obstructing calculi can be performed through shock wave lithotripsy, percutaneous nephrolithotomy, or cystoscopy and ureteroscopy for bladder and ureteral stones, respectively. Long-term prevention of stones depends on the exact metabolic abnormality but often includes increasing water intake and decreasing salt intake, since sodium excretion obligates increased calcium excretion as well.

### *Sexual Abuse*

An estimated 1 in 4 girls and 1 in 10 boys will suffer sexual abuse before adulthood, and there are no predictive socioeconomic factors. Sexual abuse as a cause of UTI should be considered in children with genital, perineal or anal bruising, abrasions, or lacerations, but external findings are not always present or typical. Abused children may also present with secondary incontinence (i.e., wet after at least 6 months of continence), low self-esteem, and a pathologic fear of examination. Suspected cases of sexual abuse must be reported to child protection services; this can be facilitated by specialized intake providers where available.

### *Dysfunctional Voiding Syndrome*

Dysfunctional voiding syndrome refers to dysfunction of the lower urinary tract in the absence of any apparent organic cause. In broad terms, dysfunctional voiding is lack of coordination between bladder muscle (detrusor) function and external sphincter activity. Two major categories of children with dysfunctional voiding are those with "lazy", high capacity bladders with little sensation and contractile activity, and those with overactive bladders that lead to frequency and urgency. Dysfunctional voiding in children with overactive bladders is thought to be due to poor cortical control over inhibition of reflex bladder contractions. Certainly, behavior is crucial to the pathophysiology of most types of dysfunctional voiding. Dysfunctional voiding can lead to secondary VUR, and may be exacerbated by chronic constipation because of alterations in pelvic floor activity caused by impacted stool. These factors are thought to contribute to bacteriuria and UTI. Diagnostic studies that are helpful in children with dysfunctional voiding include renal sonography, which can detect hydronephrosis in severe cases, VCUG, which can reveal VUR, a KUB, which can show impacted stool, and urodynamics. Treatment of dysfunctional voiding consists of behavioral

modification (i.e., timed voids), bowel regimens, pelvic floor relaxation training (biofeedback), anticholinergic medications, and short-term prophylactic antibiotics.

## SUMMARY

- UTIs affect many children and have a significant healthcare impact.
- Bacterial UTIs are associated with structural abnormalities of the urinary tract and also with acquired causes such as dysfunctional voiding, urinary stones and sexual abuse.
- Fungal UTIs have associated risk factors that include immunosuppression, underlying structural abnormalities of the urinary tract and invasive vascular access lines.
- Bacterial pyelonephritis carries the risk of renal scarring and subsequent renal insufficiency and hypertension.
- The most common radiologic studies for children with UTI are renal and bladder ultrasound and VCUG.
- Antibiotic treatment and prophylaxis are effective in treating and preventing UTI, but inappropriate antibiotic use has led to an increase in bacterial resistance.
- UTI may be a sentinel event signaling the existence of an underlying congenital urinary tract abnormality, and the differential diagnosis must include this possibility.

## REFERENCES

1. Martin, A.D. and Peters, C.A.: Vesicoureteral reflux. AUA Update Series 2013; vol 32, lesson 18, pp 174-179
2. Marotte, J., Lee, K., and Shortliffe, L.: Cystitis in infants and children. AUA Update Series 2005; vol 24, lesson 19
3. Wong, I.Y., Shortliffe, L. : Cystitis. In: Pediatric Urology for the Primary Care Physician. Eds: Rabinowitz, R., Hulbert, W.C., Mevorach, R.A. Current Clinical Urology, Eric Klein series editor. Humana Press 2015. Chapter 12, pp. 87-94
4. Freedman, A. L.: Urologic diseases in North America Project: trends in resource utilization for urinary tract infections in children. J Urol, 173: 949, 2005
5. Malek, R. S., Elder, J. S.: Xanthogranulomatous pyelonephritis: a critical analysis of 26 cases and of the literature. J Urol, 119: 589, 1978

6. Craig, J. C., Irwig, L. M., Knight, J. F. et al.: Does treatment of vesicoureteric reflux in childhood prevent end-stage renal disease attributable to reflux nephropathy? *Pediatrics*, 105: 1236, 2000
7. Practice parameter: the diagnosis, treatment, and evaluation of the initial urinary tract infection in febrile infants and young children. American Academy of Pediatrics. Committee on Quality Improvement. Subcommittee on Urinary Tract Infection. *Pediatrics*, 103: 843, 1999
8. Roberts, K.B., et al: Urinary Tract Infection: clinical practice guideline for the diagnosis and management of the initial UTI in febrile infants and children 2 to 24 months. *Pediatrics* 2011; 128: 595.
9. Wan, J. Skoog, S.J., Hulbert, W.C. et al: Section on Urology response to the new Guidelines for the diagnosis and management of UTI. *Pediatrics* 2012: 129:e1051
10. Schlager, T. A.: Urinary tract infections in children younger than 5 years of age: epidemiology, diagnosis, treatment, outcomes and prevention. *Paediatr Drugs*, 3: 219, 2001.
11. Figure 1. Reference: Algorithm for management of pediatric UTI (From: Marotte, Lee, Shortliffe, AUA Update Series vol 24; Lesson 19, 2005). Legend: RB U/S renal and bladder ultrasound; CIC clean intermittent catheterization; UDS urodynamic study.

(Updated July 2016)