

MODULE 10: MALE INFERTILITY

KEYWORDS: INFERTILITY, AZOOSPERMIA, OLIGOSPERMIA, SEMEN ANALYSIS, VARICOCELE

LEARNING OBJECTIVES:

At the end of medical school, the medical student will be able to...

1. Describe the hypothalamus-pituitary-gonadal (HPG) axis
2. Describe the workup for male infertility, including the importance of the physical exam
3. Restate the limitations of the semen analysis
4. List some common reversible causes of infertility and their treatments
5. Recognize when to refer a patient for ART

Introduction

Approximately 15% of couples will be unable to conceive after attempting unprotected intercourse for one year. Of these couples, about 50% of them will have some male factor to that is contributing to their infertility (a male factor is the sole reason in approximately 20% of infertile couples). (Thonneau P, 1991) Male infertility can be due to a variety of genetic, anatomic, and environmental conditions, many of which will be briefly discussed below. When a cause for an abnormal semen analysis cannot be found, it is termed idiopathic. When a man is infertile with a normal semen analysis and workup, the term unexplained infertility is used. As the word suggests, these men do not have a known cause for their infertility but it is thought to likely be due genetic defects that have not been described yet. The purpose of evaluation is to identify possible conditions causing infertility and treating reversible conditions which may improve a man's fertility potential. These treatments can include, medication, vitamin supplementation, surgery, and/or assisted reproductive technologies (ART).

Workup and Evaluation

History and physical exam are incredibly important in the workup of the infertile male. In fact, the decision to offer certain surgeries to these patients can be based solely on physical exam findings such as the presence of a varicocele.

A thorough and complete history should include:

- Male infertility risk factors such as a history of bilateral cryptorchidism, vasectomy, chemotherapy or radiation treatments
- Female infertility risk factors, including advanced female age (over 35 years)
- Reproductive history
 - coital frequency and timing
 - duration of infertility and prior fertility
 - childhood illnesses and developmental history
 - systemic medical illnesses (e.g., diabetes mellitus and upper respiratory diseases)
 - sexual history including sexually transmitted infections;
 - gonadal toxin exposure including heat and testosterone
- Surgical history (with a focus on GU and inguinal surgery)
- A review of medications (prescription and non- prescription) as many drugs can contribute to infertility
- Lifestyle exposures such as alcohol, marijuana, and tobacco use as well as vocational exposures
- Family reproductive history

As mentioned before, the physical exam is very important in the workup of a man with infertility, with particular focus on the GU (genitourinary) exam. This should include:

- Examination of the penis including the location and size of the urethral meatus
- Palpation of the testes and measurement of their size
- Presence and consistency of both the vas deferens and epididymides
- Presence of a varicocele
- Secondary sex characteristics including body habitus, hair distribution and breast development;

When a varicocele is palpated it is graded as follows:

- Grade 0 (subclinical): seen on ultrasound only but not physically palpable
- Grade I: palpable when the patient is performing the Valsalva maneuver
- Grade II: palpable without Valsalva
- Grade III: able to visualize varicocele through scrotum (“bag of worms”)

The diagnosis of congenital bilateral absence of the vasa deferens (CBAVD) and varicocele is established by physical examination. Scrotal exploration and imaging is not needed to make these diagnoses so make sure a good physical exam is part of your work up for any man who complains of infertility!

Semen Analysis

The cornerstone of a male infertility workup is the semen analysis. The most current guidelines for this are published by the WHO (World Health Organization) and are on their 5th edition. (World Health Organization, 2010) There are several important

things to know about a semen analysis to be able to properly interpret the results. First, it should be examined under the microscope within one hour of collection and should the sample should be given after 2-3 days of abstinence. A proper semen analysis takes time and very specialized training by the andrologist so ideally these this test is done at a center that does a lot of them. While many routine laboratory tests have a relatively set cut off point between normal and abnormal (white blood cell count, troponins, creatinine, etc.), semen analysis do not really have this kind of differentiation despite what the “normal” lab values you will see listed net to most semen values. This is because of how the data was originally designed. Essentially, the original studies involved taking a bunch of men who had conceived with their partner within the last year and having them perform a semen analysis. A large bell curve distribution was noted and the authors somewhat arbitrarily decided that anything better then the *5th percentile* would be considered “normal”. This means that a patient with a barely “normal” semen analysis still has worse semen parameters then 95% of fertile men! (Cooper TG, 2010) This is an important fact to consider when interpreting results and counseling patients. Despite these limitations, it is still the single best test we have when evaluating these patients. Below are the “normal” values based on the most recent data.

Semen Parameter	WHO 5th Ed. (2010)
Volume	1.5 ml
Appearance	Grey and opaque
pH	> 7.2
Concentration	> 15 million/ml
Motility	> 40% (> 32% progressive)
Morphology	> 4% normal forms (strict criteria)
Leukocytes	< 1 million/ml

Blood Tests

Blood tests focus on testing for hormonal and genetic causes of infertility. The figure below shows the important hormones involved in the hypothalamus-pituitary-gonadal (HPG) axis (figure 1). The hypothalamus makes GnRH (gonadotropin releasing hormone) to stimulate the pituitary gland. This in turn causes the pituitary to release FSH (follicle stimulating hormone) and LH (luteinizing hormone). FSH Acts on Sertoli cells to initiate meiosis and spermatogenesis. It also causes the Sertoli cells to release Inhibin, a molecule that causes negative feedback inhibition. LH acts on Leydig cells to stimulate the production of testosterone which also acts as a potent negative inhibitor of FSH and LH release from the pituitary. Estradiol is made from conversion of testosterone by aromatase. Derangement of one or more of these hormones can lead to fertility problems. Some of the common abnormalities will be described in the next section.

Genetic testing (karyotype and Y-chromosome microdeletion) should be performed on any patient with severe oligospermia. More advanced testing such as sperm DNA fragmentation can also be done but is outside the scope of this discussion.

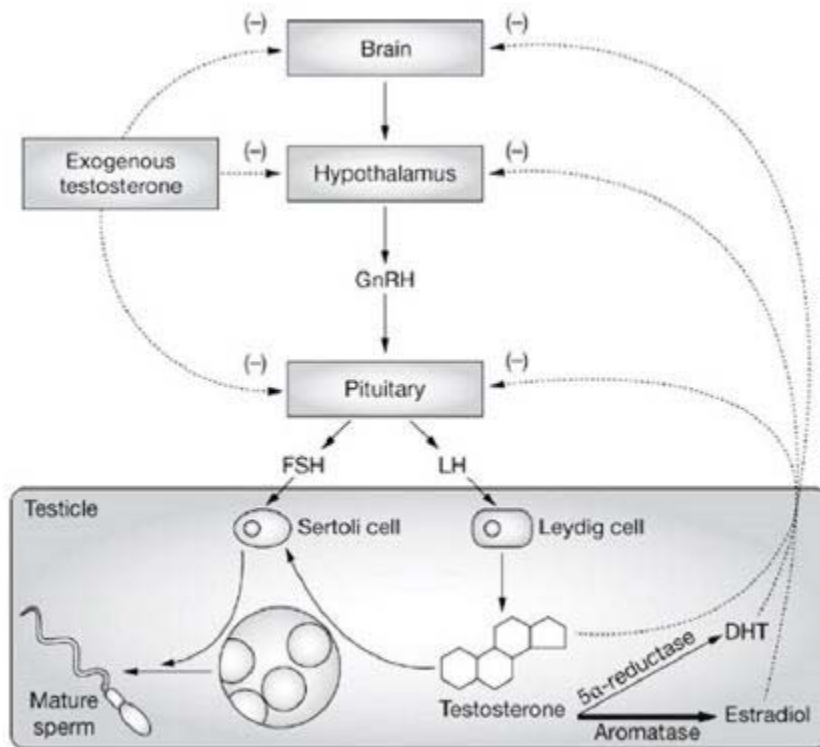


Figure 1: hypothalamus-pituitary-gonadal (HPG) axis

Imaging

Scrotal ultrasound, transrectal ultrasound, brain MRIs, and CT scans are all indicated depending on the diagnosis and work up. Scrotal ultrasound is good for diagnosing testicular tumors and confirming the presence of a varicocele in obese or otherwise difficult to examine patients. A transrectal ultrasound can help diagnose ejaculatory duct obstruction and a brain MRI can rule out a prolactinoma as a cause of infertility if their prolactin is elevated.

Pathology

Many anatomic, hormonal, and genetic abnormalities can cause male infertility. Primary infertility describes a man who has never fathered a child while secondary infertility is the term used when a man has previously fathered a child but is now having trouble conceiving. Below is a short description of some of the most commonly seen diagnoses and their treatments. A few more important terms to know when discussing abnormal fertility findings include:

- Azoospermia: absence of sperm
- Oligozoospermia: low sperm count

- Severe Oligospermia: very low sperm count (<5 million/ml)
- Asthenozoospermia: poor sperm motility
- Teratozoospermia: abnormal sperm morphology

Obstructive Azoospermia

Azoospermia can come in two flavors, *non-obstructive* and *obstructive*, and they are treated very differently.

Obstructive azoospermia is due to an obstruction/blockage somewhere between the testicle and the seminal vesicles and may occur in up to 7% of the infertile population. An obstruction between the seminal vesicles and prostate is called an ejaculatory duct obstruction (EDO) and will be discussed later. Patients with obstructive azoospermia will have a semen analysis with no sperm, but normal pH and volume. A common cause of obstructive azoospermia is a previous vasectomy. There are 3.6 million vasectomized men in the United States alone, which represents an overall vasectomy prevalence of 6-8% based on several large national cohorts. (Eisenberg ML, 2010) Up to 7% of these men desire restoration of fertility and at least 2% undergo a vasectomy reversal. Other causes of obstruction include hernia repair. Damage to the vas deferens during adult hernia repair is uncommon, but patients who have undergone bilateral hernia repair as children have vasal obstruction rates as high as 40%. (Matsuda T, 1998) Sexually transmitted infections, previous groin/GU surgery, and trauma can also cause obstruction. These obstructions can often times be fixed with a vasovasostomy or a vasoepididymostomy with excellent results. Using small sutures (9-0 and 10-0) the obstruction can be bypassed. When the obstruction is in the vas and one is able to sew the vas directly back to the vas, success rates are around 90%. When the vas must be connected to the epididymis, rates of sperm return drop to around 60-70%.

Finally, obstructive azoospermia can be caused by congenital bilateral absence of the vas deferens. This is seen when a patient is a carrier of the CFTR (cystic fibrosis) gene. These patients will have low volume azoospermia and no palpable vas on examination. Fortunately, they usually do not have a problem with sperm production and their sperm can be harvested with a small surgical procedure such as a PESA (*Percutaneous Epididymal Sperm Aspiration*) or TESE (*Testicular Sperm Extraction*). When seeing a patient with this diagnosis, it is imperative to have the partner checked for their CFTR carrier status as well.

Nonobstructive azoospermia is a failure of the testis to produce sperm. This is classically diagnosed with an elevated FSH, small testis on exam and normal volume azoospermia seen on semen analysis. The causes of this are multifactorial and can include genetic abnormalities, medications (chemotherapy, testosterone, radiation), infections, and idiopathic causes. The most common genetic cause is Klinefelter's disease (a phenotypic male with 47, XYY). Other genetic syndromes include primary ciliary dyskinesia (Kartagener's Syndrome) which can be treated with in-vitro fertilization and Kallmann Syndrome (absence of GnRH production) which can be

treated with exogenous replacement of LH and FSH. Until recently, there were no treatments for the other causes of nonobstructive azoospermia until it was determined that there may be small pockets of sperm production within a testis despite not making enough sperm to make it into the ejaculate. In this setting, a microscopic testicular sperm extraction (microTESE) can be offered to these patients. In this procedure, an operating microscope is used to carefully dissect a large portion of the testis. The goal is to find testicular tubules that seem healthy and plump. These are then resected and examined under a regular light field microscope for the presence of sperm that can then be used for invitro fertilization. Depending on the etiology, this procedure is successful 20-60% of the time.

Ejaculatory Duct Obstruction

Another form of obstruction is when the seminal vesicles (SV) are unable to drain into the prostate due to ejaculatory duct obstruction (EDO). Semen analysis will show minimal volume (the majority of ejaculate volume is produced by the seminal vesicles), acidic pH (prostatic fluid is acidic and seminal vesicle fluid is basic) and severe oligospermia. Usually there will be severe oligospermia or azoospermia. Further diagnosis can be made with a transrectal ultrasound of the prostate that will reveal dilated SVs and aspiration will often times reveal sperm. Occasionally, enough sperm can be obtained from this aspiration to be used for in-vitro fertilization (IVF) but usually a transurethral resection of the ejaculatory ducts (TURED) is needed. This is similar to a TURP or other transurethral resection, but just the area just lateral to the verumontanum is resected. When this is successful the ejaculatory ducts will be resected, and patients will often have return of normal semen parameters. Sterile epididymitis is the most common side effect from the procedure because the one way valve effect of the ejaculatory duct is removed allowing urine to flow in a retrograde fashion down the vas and into the epididymis.

Varicocele

Varicoceles, an abnormal dilation of the veins of the pampiniform plexus, are the most common cause of secondary infertility. They are also incredibly common in the general population with a prevalence around 20% with the vast majority of varicoceles forming on the left side due to venous anatomy. Not all varicoceles are symptomatic though and only those causing semen analysis abnormalities or discomfort should be fixed. The exact etiology of how a varicocele can cause infertility is still debated, but it is most likely due to thermal dysregulation. (Tadros & Sabanegh Jr., 2017) The dilated veins cause blood to pool around the testis which causes the intratesticular temperature to increase. Since optimal spermatogenesis occurs at a temperature lower than body temperature (hence why the testes are located outside the body and in the scrotum), the increased blood pooling will cause a decrease in sperm production and quality. On semen analysis, one can see oligospermia, asthenozoospermia, and/or teratozoospermia.

Treatment is relatively straight forward and involves ligation of the abnormal veins. This can be done via multiple approaches, but the gold standard is a sub-inguinal

microscopic varicocelectomy. This procedure is done through a small incision below the external inguinal ring. The Spermatic cord is brought up through the incision and an operating microscope is used to identify and ligate large veins. Care is taken to not damage the arterial supply (with use of intraoperative doppler) and the vas.

Idiopathic Male Infertility

Unfortunately, many men seen for infertility and abnormal semen analyses have no obvious cause for their condition. This frustrating for both the physician and patient. While we may not know the cause of their problem, there are still some treatments that can help these men. First line therapy includes behavioral modification including quitting smoking, weight loss if needed, avoiding activities with scrotal/perineal pressure (bike riding), and avoiding long exposure to wet heat (sauna, hot tub). In addition there is some medical therapy available. The most common medication used is clomiphene citrate. This medication is a selective estrogen receptor modulator (SERM). It acts by blocking the negative feedback of estrogen on the hypothalamus and pituitary which causes a downstream increase of FSH and LH. This in turn can stimulate spermatogenesis within the testis. Many of these patients also have low testosterone and the increase in LH will also increase their testosterone without harming sperm production. Another commonly used class of medications are the aromatase inhibitors, anastrozole being the most common in the United States. This medication acts by blocking the conversion of testosterone to estradiol in the adipose tissue. It is most effective when there is a greater than 10:1 ratio of estrogen to testosterone.

An increasingly recognized cause of idiopathic infertility is oxidative stress. This may be the common pathway of many insults. In fact, a new term has been proposed, Male Oxidative Stress Infertility (MOSI). (Agarwal A, 2019) Treatment of this condition as well as many others is with antioxidants. Which antioxidants as well as the correct dose is still hotly debated and the focus of multiple research studies. (Smits RM, 2019) Commonly used antioxidants include vitamin C, vitamin E, zinc, l-carnitine, co-enzyme Q10, and many others. The jury is out on whether or not these antioxidants improve fertility outcomes, but the cost and side effect risk is so low that many physicians routinely recommend them to their infertile men.

Finally, assisted reproductive technologies such as intrauterine insemination (IUI) and IVF can overcome many potential causes of idiopathic infertility. This is also the treatment of choice for *unexplained infertility* which is infertility despite a completely normal workup of both the man and female partner.

References

Agarwal A, P. N. (2019). Male oxidative stress infertility (Mosi): proposed terminology and clinical practice guidelines for management of idiopathic male infertility. *World J Mens Health, 37*(3), 296-312.

Cooper TG, N. E. (2010). World Health Organization reference values for human semen characteristics. *Hum Reprod Update, 16*(3), 231-245.

Eisenberg ML, L. L. (2010). Estimating the number of vasectomies performed annually in the United States: data from the National Survey of Family Growth. *J Urol, 184*(5), 2068-2072.

Matsuda T, M. K. (1998). Seminal tract obstruction caused by childhood inguinal herniorrhaphy: results of microsurgical reanastomosis. *J Urol*(159), 837-40.

Smits RM, M.-P. R. (2019). Antioxidants for male subfertility. *Cochrane Database Syst Rev, 3*, CD007411.

Tadros, N. N., & Sabanegh Jr., E. (2017). Ch. 12: Varicocele. In *Treatment of Male Infertility: a Case-based Guide for Clinicians*. Springer.

Thonneau P, M. S. (1991). Incidence and main causes of infertility in a resident population (1,850,000) of three French regions (1988-1989). *Hum Reprod, 6*, 811.

World Health Organization. (2010). *WHO laboratory manual for the examination and processing of human semen* (5th ed.). Geneva: World Health Organization.

(Updated October 2020)